Precancerous lesion of rectum

DR Ahmad Shavakhi M.D

Isfahan university of medical sciences

Colon Adenoma-Adenocarcinoma Pathway

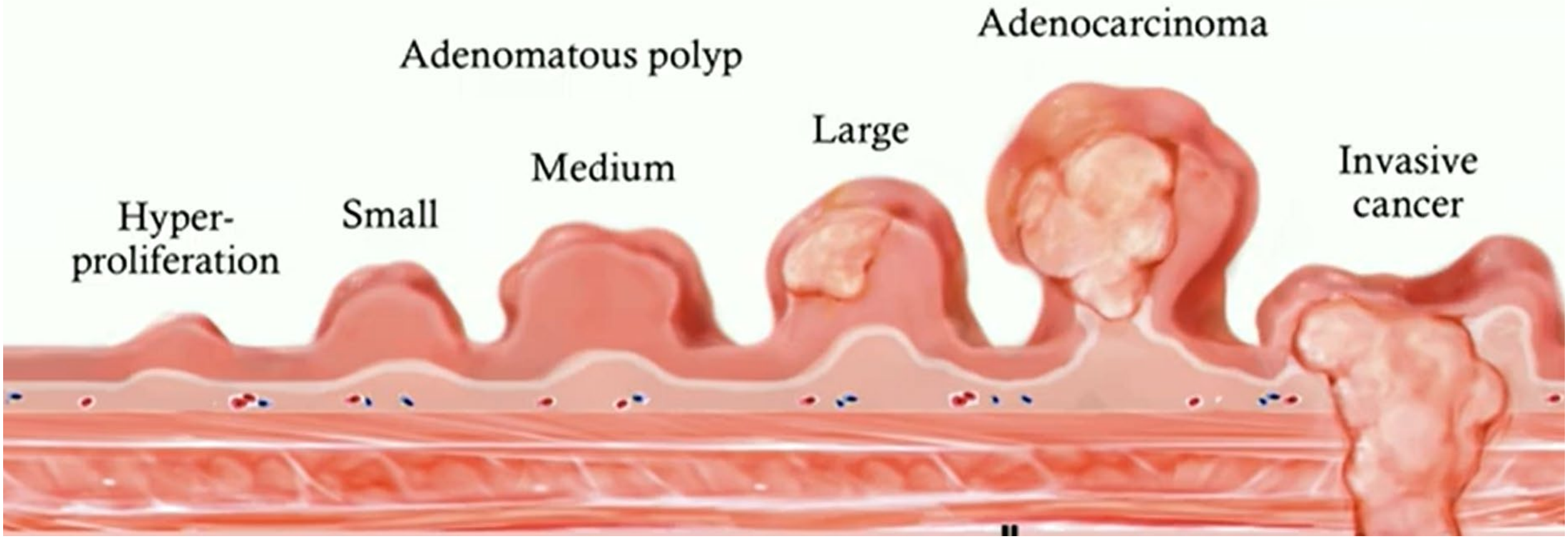

Lasting about 10 years

Assessment of the Large Colon Polyp

1. Surface pattern

2. Morphology

3. Histology

Assessment of the Large Colon Polyp

- Size — small vs. large
- Shape — pedunculated vs. sessile
- Location — IC valve, appendiceal orifice, rectum
- Orientation — easy vs. difficult

Assessment of the Large Colon Polyp

1. Surface pattern
   - NICE classification
   - Kudo Pit Pattern classification
2. Morphology
   - Paris classification
   - Non-lifting sign
   - Laterally spreading tumor
3. Histology
   - Haggitt classification
   - Kikuchi classification

Surface pattern

NICE Classification

	Type 1	Type II	Type III
Color	Same or lighter than background	Brown relative to background	Brown to dark brown relative to background
Vessels	None	Brown vessels surrounding white structures	Disrupted or missing vessels
Surface Pattern	Dark uniform spots or homogeneous	Oval, tubular or branched white structure surrounded by brown vessels	Amorphous or absent surface pattern
Most likely pathology	Hyperplastic	Adenoma	Deep submucosal invasive cancer

Surface pattern



Surface pattern



Surface pattern

NICE Type III



Surface pattern

Kudo Pit Pattern

I	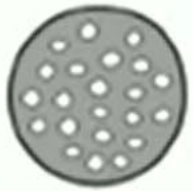	Round pit (normal pit)	
II		Asteroid pit	
IIIs		Tubular or round pit that is smaller than the normal pit (type I)	
IIIL		Tubular or round pit that is larger than the normal pit (type I)	

IV		Dendritic or gyrus-like pit	
VI		Irregular arrangement and sizes of IIIL, IIIs, IV type pit pattern	
VN		Loss or decrease of pits with an amorphous structure	

Japan NBI Expert Team (JNET) classification

NBI	Type 1	Type 2A	Type 2B	Type 3
Vessel Pattern	・Invisible*1	・Regular caliber ・Regular distribution (meshed/spiral pattern)*2	・Irregular distribution	・Loose vessel areas ・Interruption of thick vessels
Surface Pattern	・Regular dark or white spots ・Similar to surrounding normal mucosa	・Regular (tubular/branched/papillary)	・Irregular or obscure	・Amorphous areas
Most likely histology	Hyperplastic polyp/ Sessile serrated polyp	Low grade intramucosal neoplasia*4	High grade intramucosal neoplasia*5/ Superficial submucosal invasive cancer*3	Deep submucosal invasive cancer
Examples	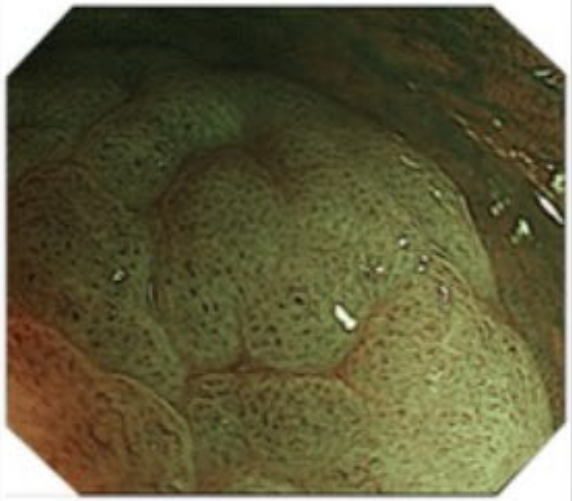	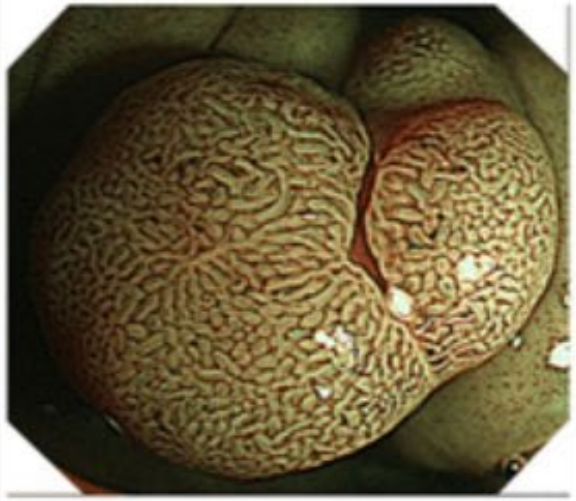	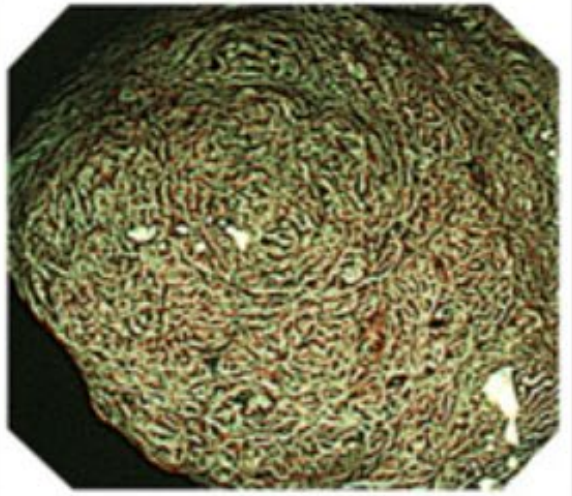	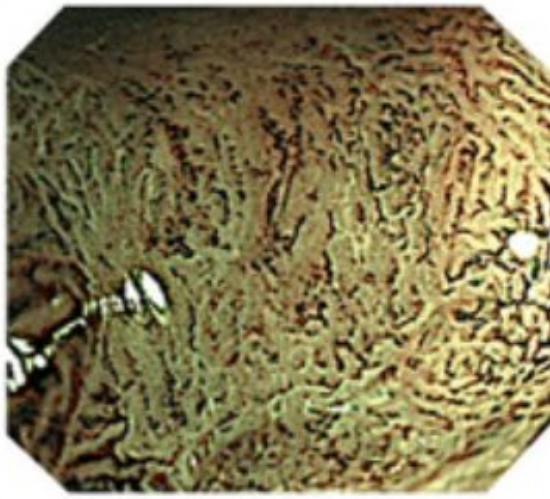

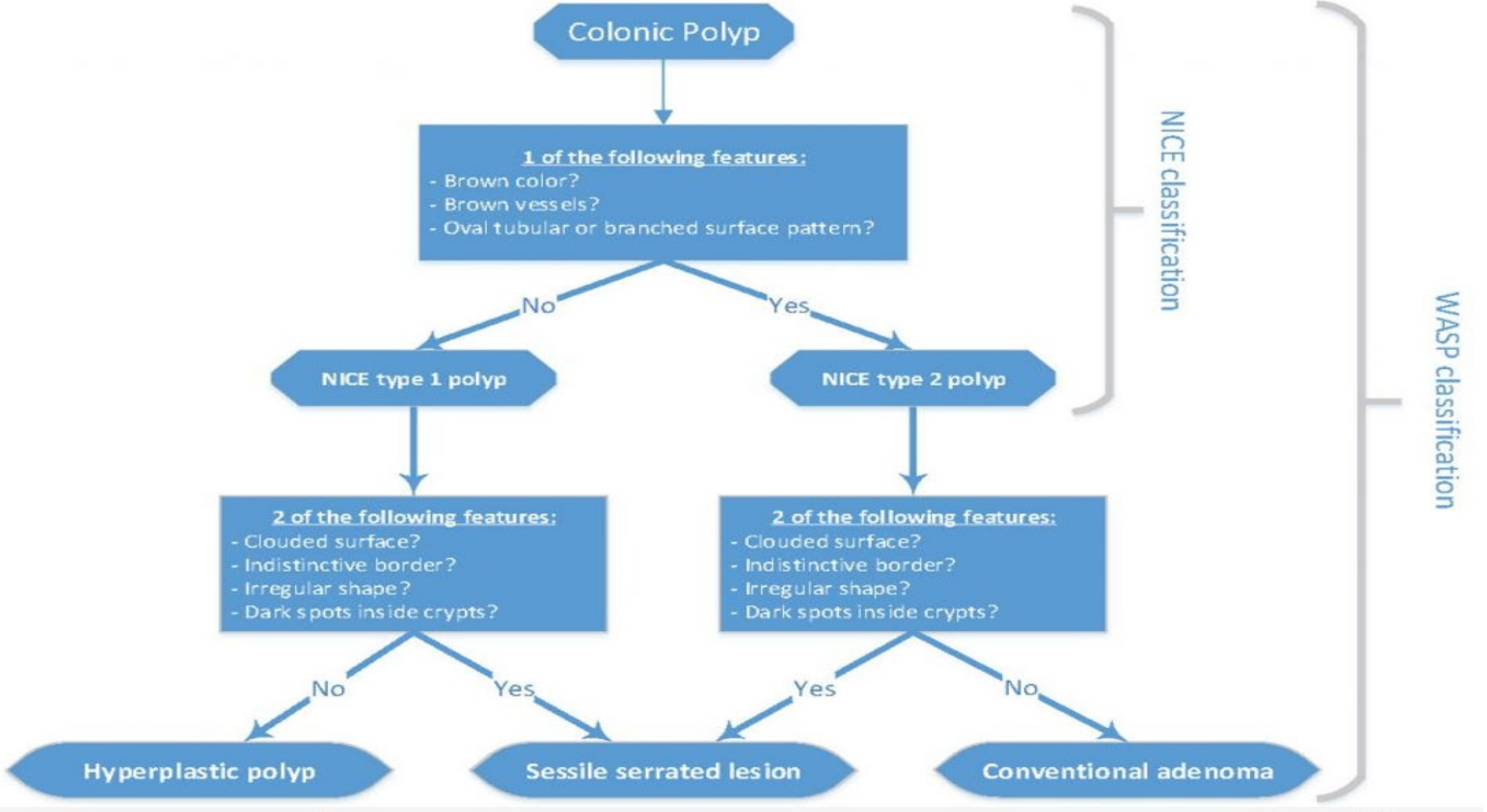
Colonic Polyp
1 of the following features:
- Brown color?
- Brown vessels?
- Oval tubular or branched surface pattern?
No
Yes
NICE type 1 polyp
NICE type 2 polyp
2 of the following features:
- Clouded surface?
- Indistinctive border?
- Irregular shape?
- Dark spots inside crypts?
2 of the following features:
- Clouded surface?
- Indistinctive border?
- Irregular shape?
- Dark spots inside crypts?
No
Yes
Yes
No
Hyperplastic polyp
Sessile serrated lesion
Conventional adenoma
NICE classification
WASP classification

Sessile serrated lesion

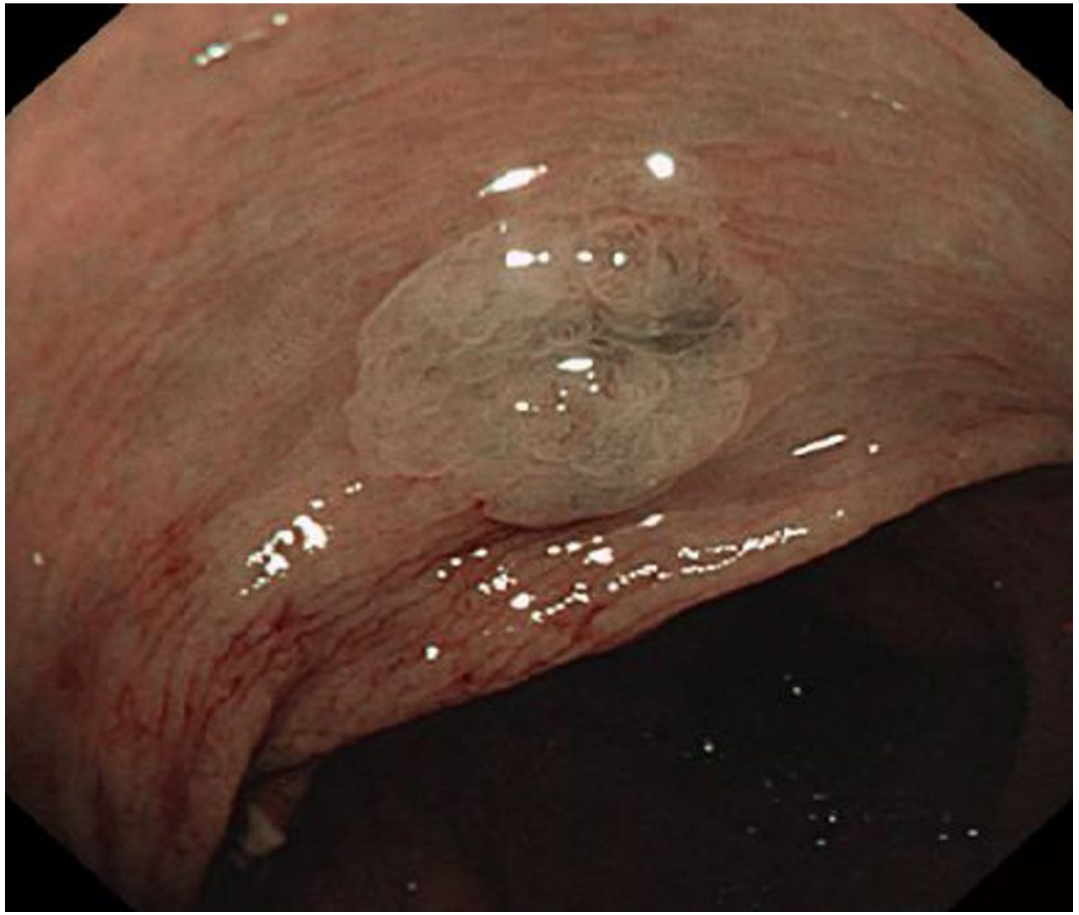

Morphology

Paris Classification

- Endoscopic classification for superficial colorectal lesions
- 3 major superficial morphologies

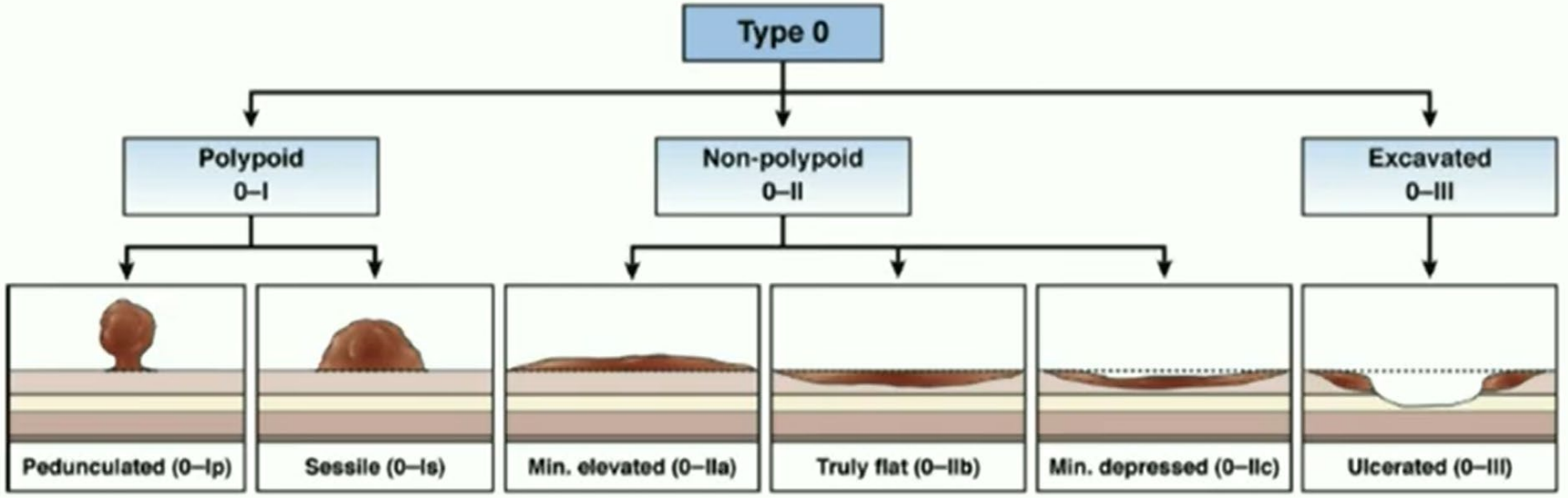

Morphology

Laterally Spreading Tumors

Granular



Non-Granular

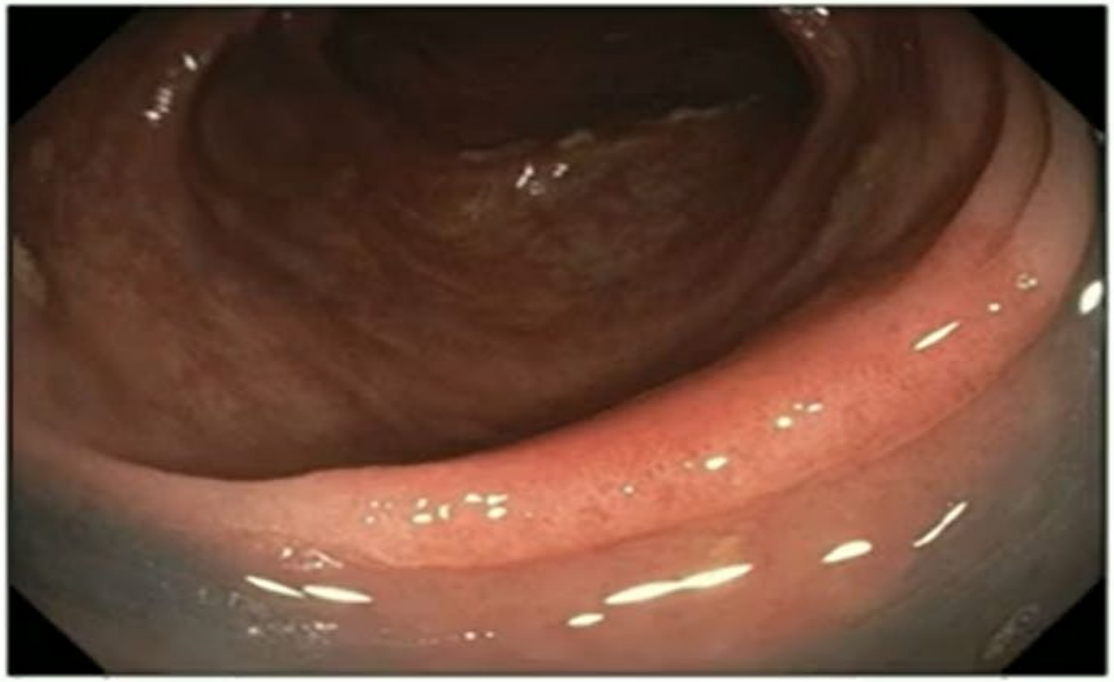

Non-Lifting Sign

- Fluid injected under the polyp fails to lift the lesion
- Suggests deep submucosal invasion
  - Especially if no prior attempted resection
- Also seen in fibrosis from prior biopsy, cautery, tattoo

Histology

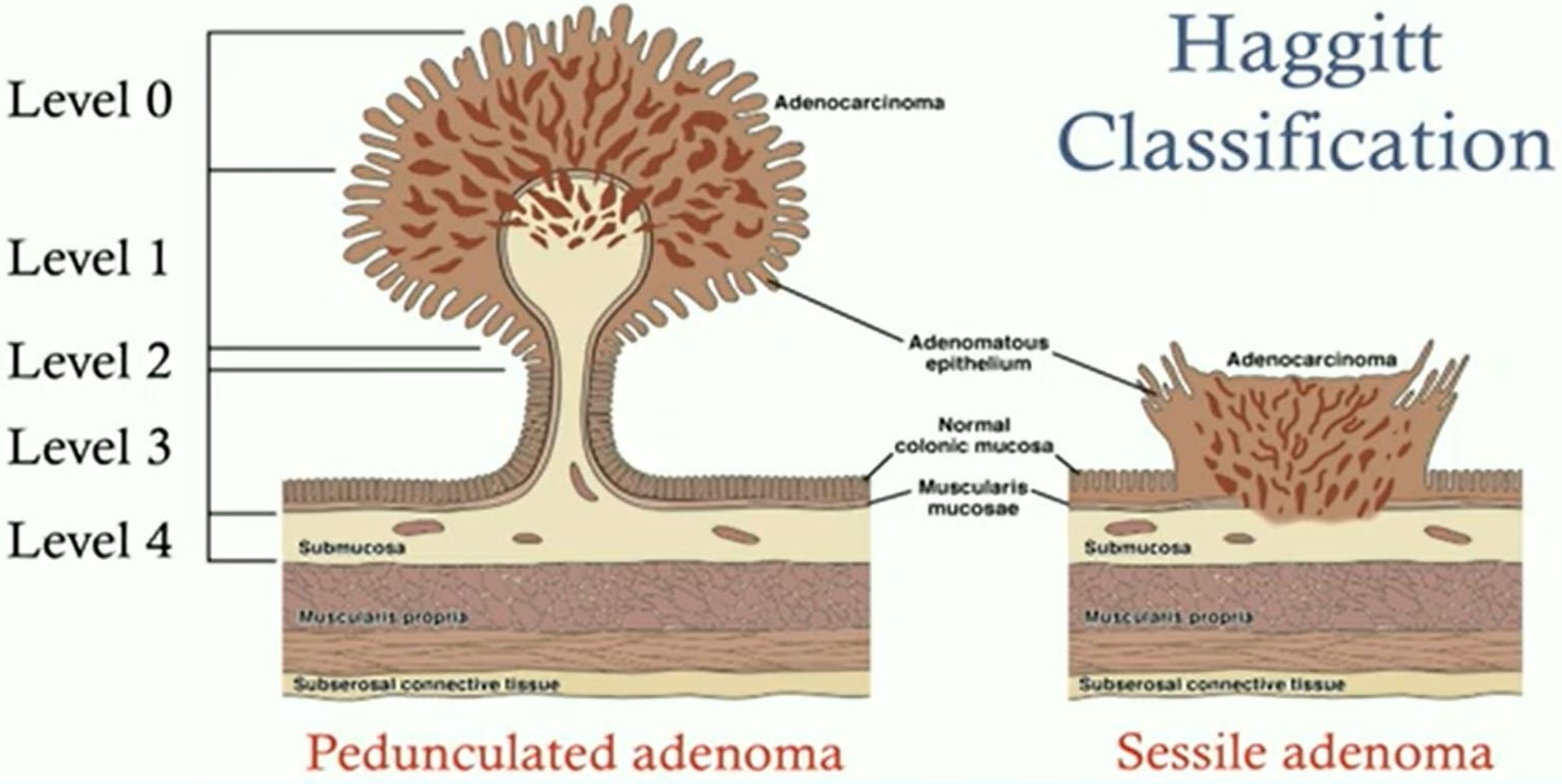
Haggitt Classification
Level 0
Level 1
Level 2
Level 3
Level 4
Adenocarcinoma
Adenomatous epithelium
Normal colonic mucosa
Muscularis mucosae
Submucosa
Muscularis propria
Subserosal connective tissue
Adenocarcinoma
Submucosa
Muscularis propria
Subserosal connective tissue
Pedunculated adenoma
Sessile adenoma

Histology

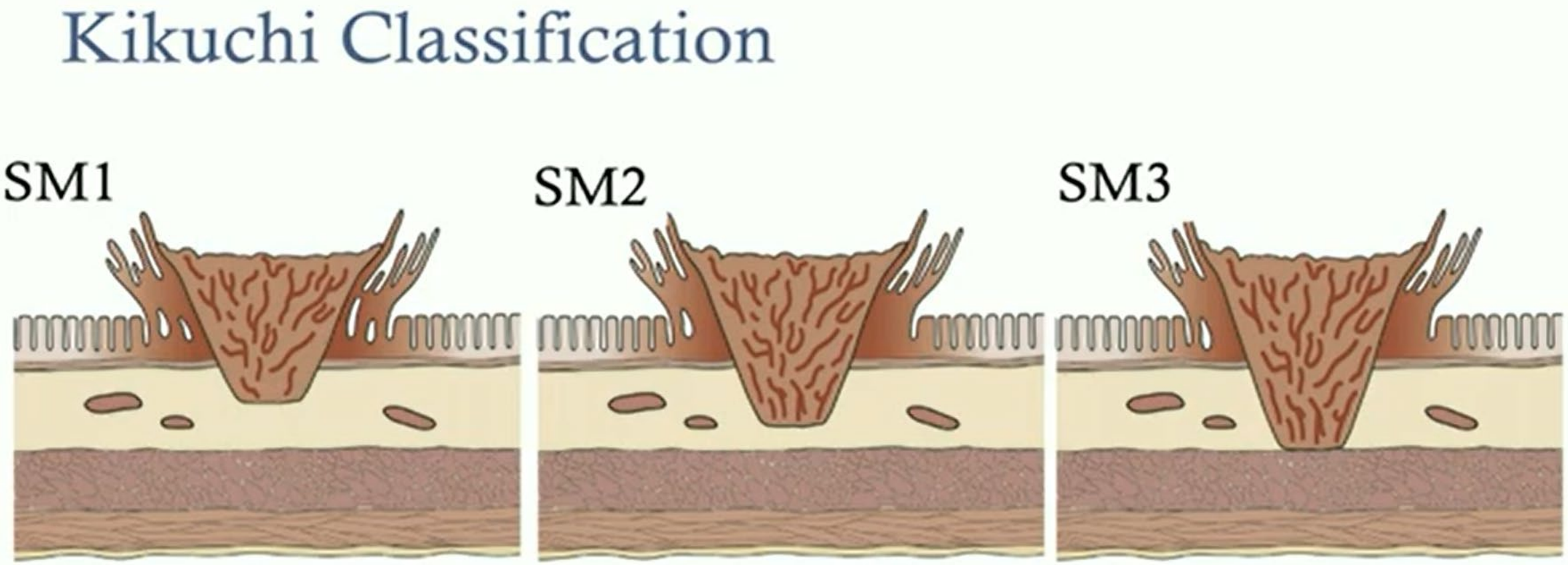

Malignant Polyp

- Colorectal polyp with neoplastic invasion of the submucosa without extension into muscularis propria

AJCC Colon Cancer Staging

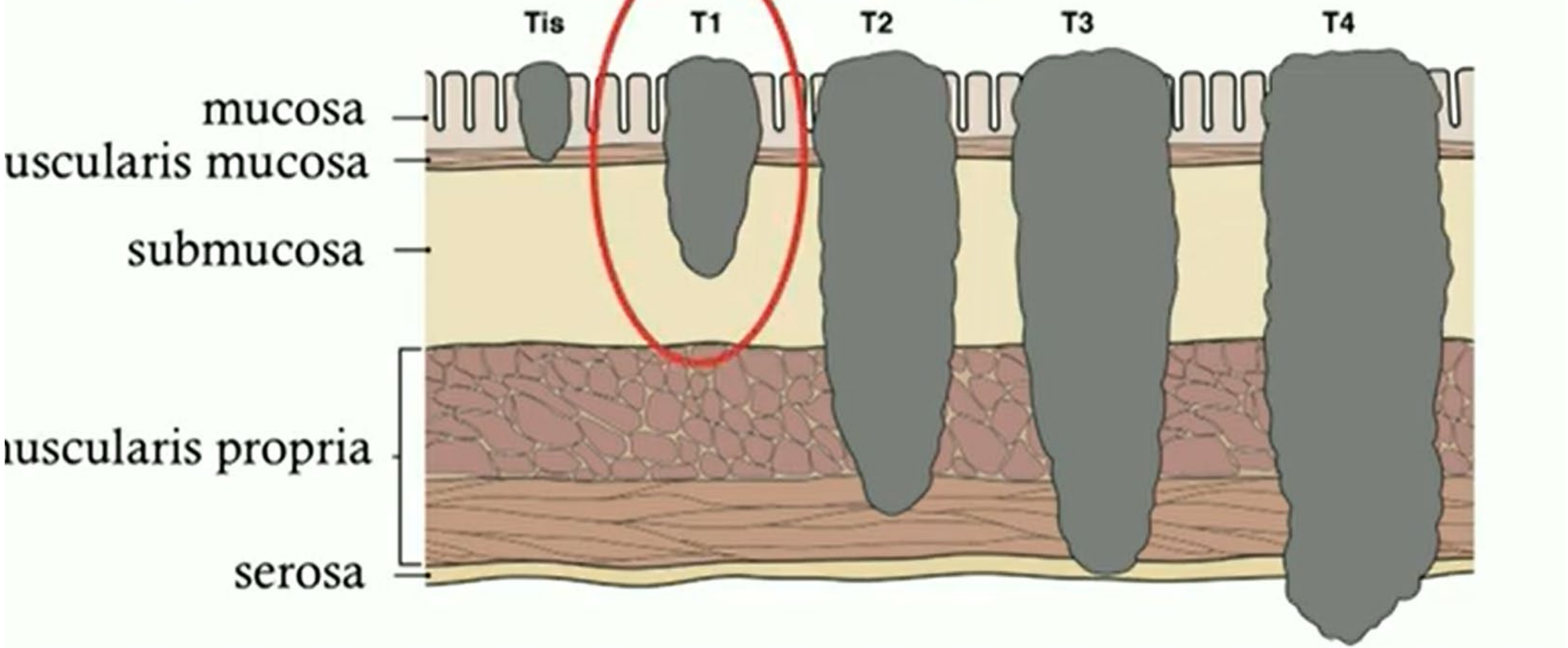

Deep Submucosal Invasion

- Definition: ≥ 1 mm submucosal invasion
- Endoscopic features are highly specific
  - NICE – Type III
  - Kudo Pit Pattern – Type Vi or Vn
  - Ulceration or depression of lesion surface
  - Non-lifting sign

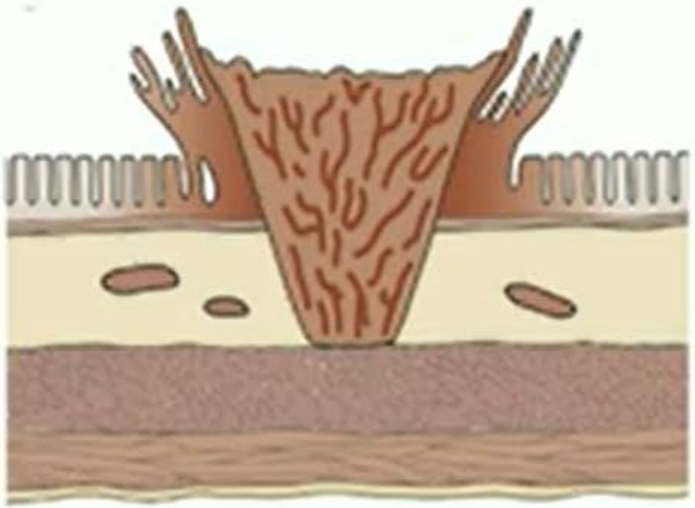

Deep Submucosal Invasion

- Definition: ≥ 1 mm submucosal invasion
- Endoscopic features are highly specific
- 10-18% risk of residual disease in bowel wall and/ lymph metastases after endoscopic resection

Superficial Submucosal Invasion

- < 1 mm invasion of submucosa
- No endoscopic signs with high sensitivity/specificity
- Endoscopic features include:
  - Size ≥ 2 cm
  - Location: right colon, rectosigmoid colon
  - LST-G with large discrete nodule
  - LST-NG

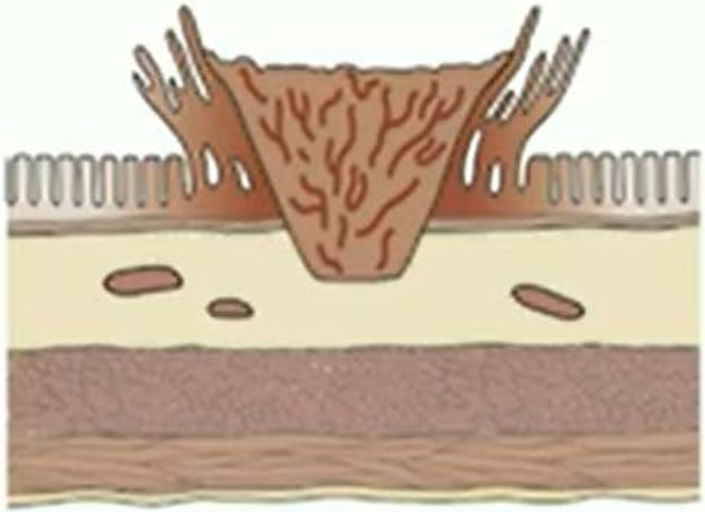

Approach to the Large Colon Polyp

1. Is the polyp pedunculated or non-pedunculated?
   - Pedunculated → endoscopic resection
   - Non-pedunculated → see next question
2. Does the polyp have endoscopic features of deep submucosal invasion?
   - Yes → biopsy, tattoo, staging, surgery
   - No → endoscopic resection

High risk features of malignant polyp

- Poorly differentiated histology.
- Lymphovascular invasion (LVI) or perineural invasion (PNI).
- Tumor budding (foci of isolated cancer cells or a cluster of five or fewer cancer cells at the invasive margin of the polyp).
- Cancer at the resection margin.
- Submucosal invasion depth ≥1 mm.

Needs surgery

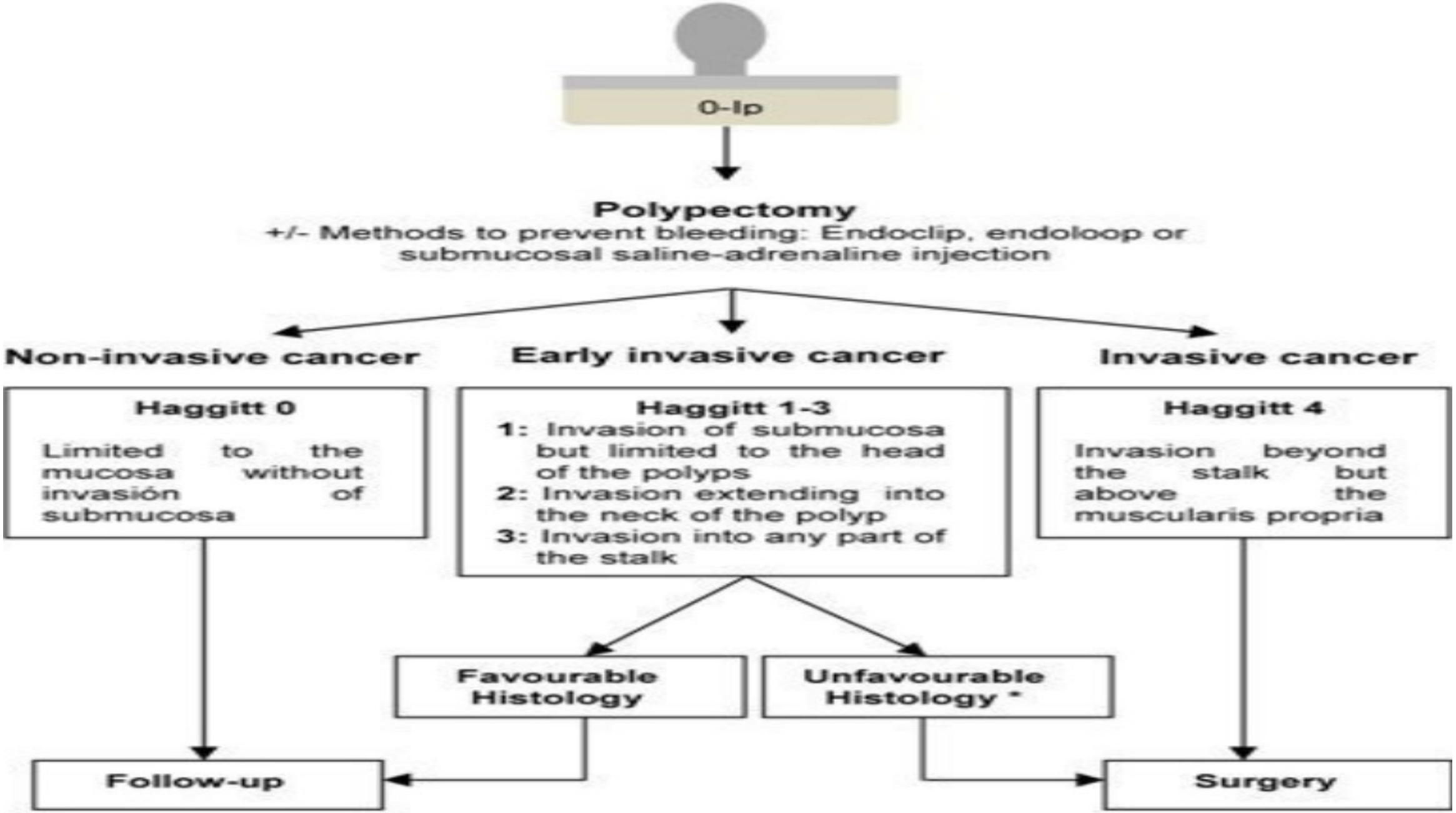

Biopsy margin ≤ 1 mm, piecemeal removal, poorly differentiated tumour, lymphatic or vascular invasion

Gastroenterology 2020;159:1916–1934

AGA SECTION

Endoscopic Recognition and Management Strategies for Malignant Colorectal Polyps: Recommendations of the US Multi-Society Task Force on Colorectal Cancer

Aasma Shaukat,[1,2] Tonya Kaltenbach,[3] Jason A. Dominitz,[4,5] Douglas J. Robertson,[6,7] Joseph C. Anderson,[6,7,8] Michael Cruise,[9] Carol A. Burke,[9] Samir Gupta,[10,11] David Lieberman,[12,13] Sapna Syngal,[14,15,16] and Douglas K. Rex[17]

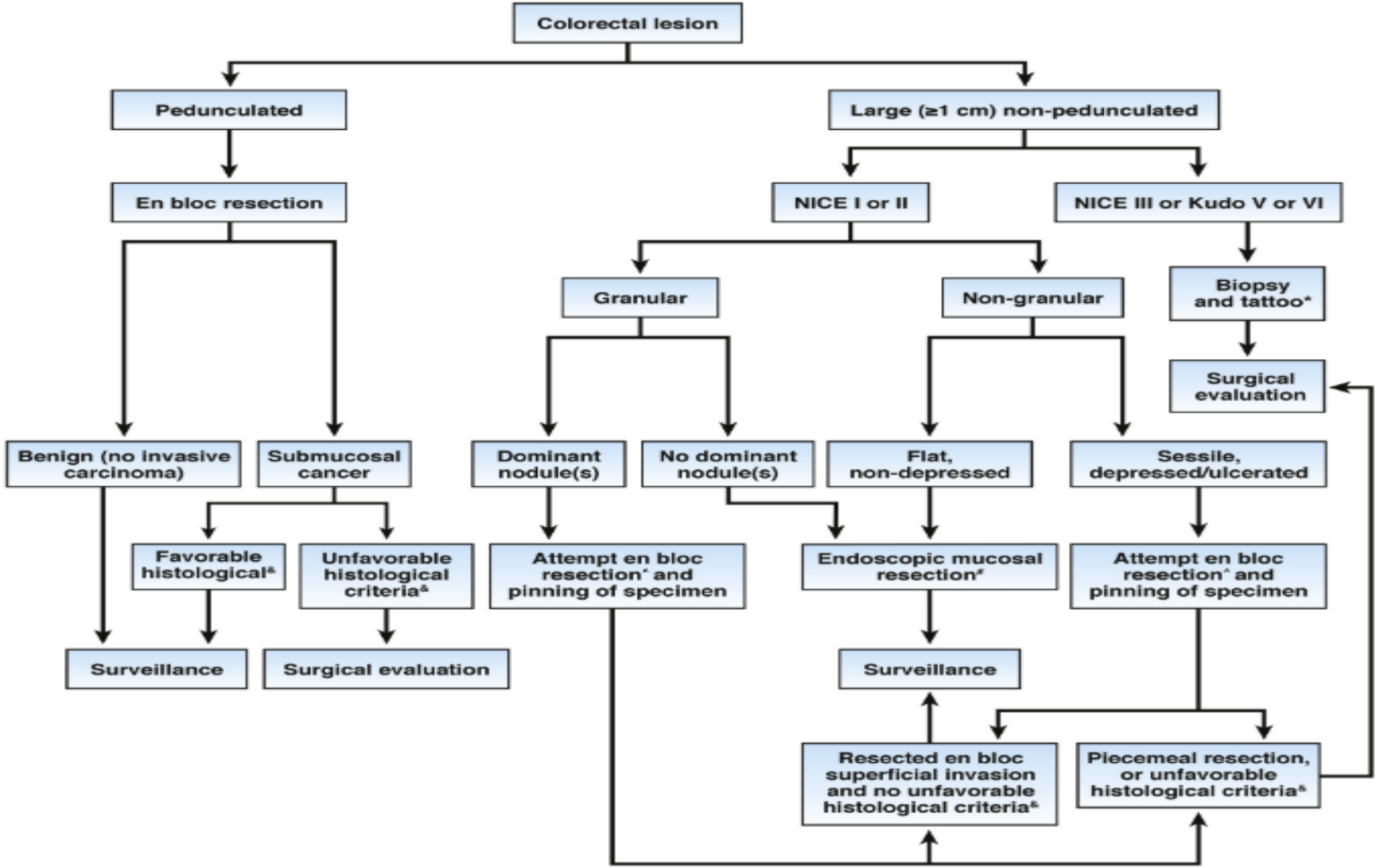
Colorectal lesion
Pedunculated
Large (≥1 cm) non-pedunculated
En bloc resection
NICE I or II
NICE III or Kudo V or VI
Granular
Non-granular
Biopsy and tattoo*
Surgical evaluation
Benign (no invasive carcinoma)
Submucosal cancer
Dominant nodule(s)
No dominant nodule(s)
Flat, non-depressed
Sessile, depressed/ulcerated
Favorable histological&
Unfavorable histological criteria&
Attempt en bloc resection^ and pinning of specimen
Endoscopic mucosal resection#
Attempt en bloc resection^ and pinning of specimen
Surveillance
Surgical evaluation
Surveillance
Resected en bloc superficial invasion and no unfavorable histological criteria&
Piecemeal resection, or unfavorable histological criteria&

Digestive Endoscopy 2024; **36**: 1253–1268 doi: 10.1111/den.14826

Original Article

International consensus on the management of large (≥20 mm) colorectal laterally spreading tumors: World Endoscopy Organization Delphi study

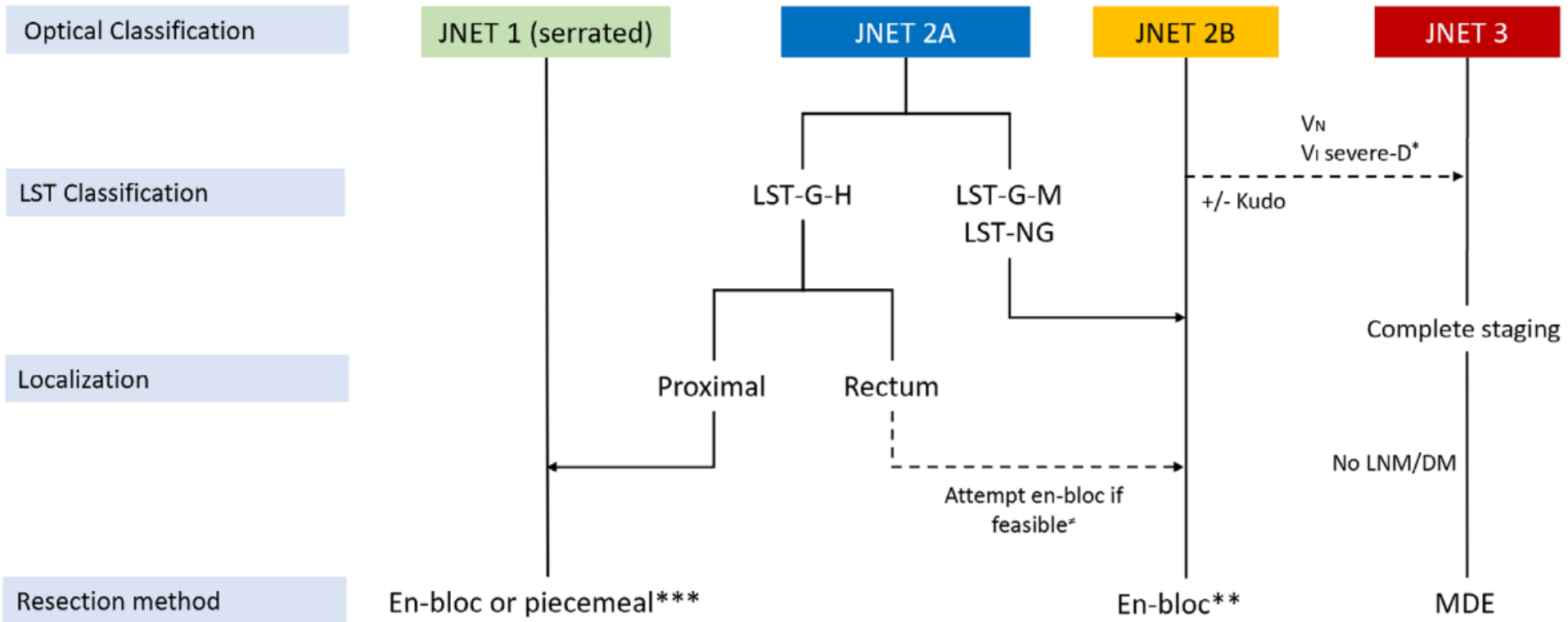
Optical Classification
LST Classification
Localization
Resection method
JNET 1 (serrated)
JNET 2A
JNET 2B
JNET 3
LST-G-H
LST-G-M
LST-NG
VN
VI severe-D*
+/- Kudo
Proximal
Rectum
Attempt en-bloc if feasible≠
Complete staging
No LNM/DM
En-bloc or piecemeal***
En-bloc**
MDE

Rectal NET

- Endoscopic appearance
  - Like hyperplastic polyps or yellowish sub-epithelial lesion ,firm with positive rolling sigh
  -

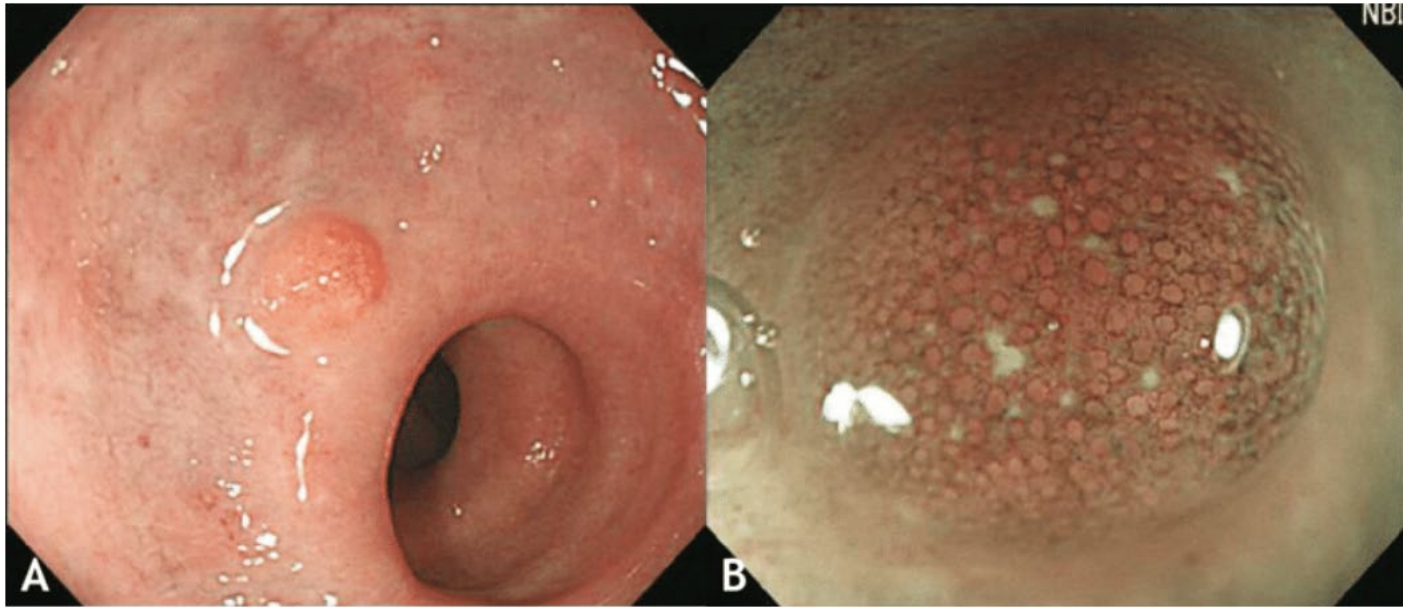

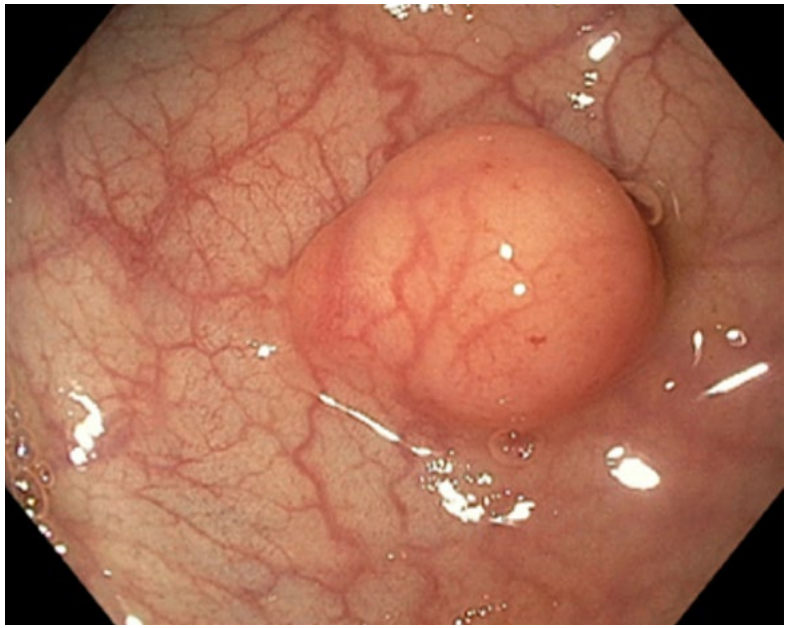

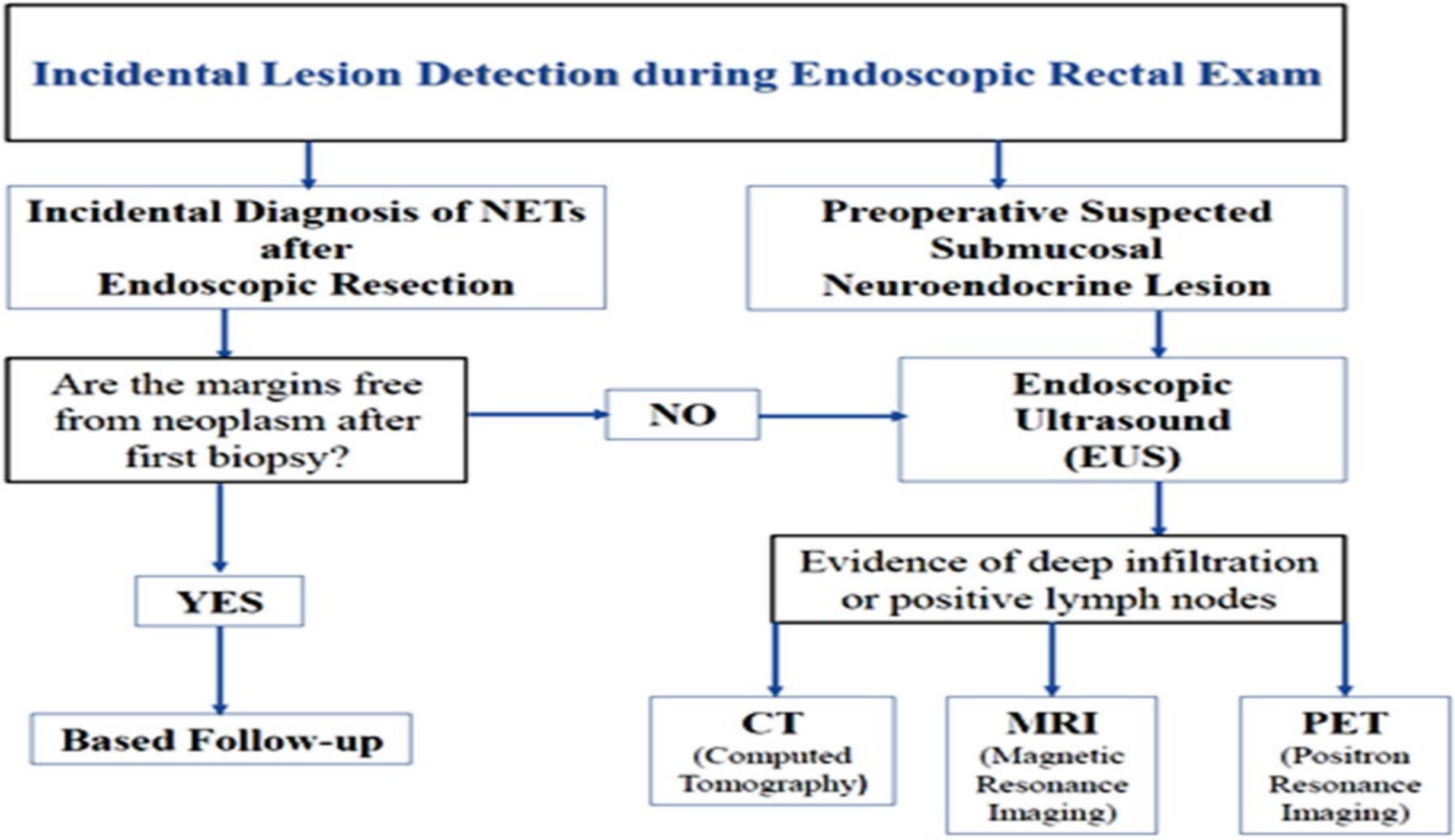
Incidental Lesion Detection during Endoscopic Rectal Exam
Incidental Diagnosis of NETs after Endoscopic Resection
Preoperative Suspected Submucosal Neuroendocrine Lesion
Are the margins free from neoplasm after first biopsy?
NO
Endoscopic Ultrasound (EUS)
YES
Evidence of deep infiltration or positive lymph nodes
Based Follow-up
CT (Computed Tomography)
MRI (Magnetic Resonance Imaging)
PET (Positron Resonance Imaging)

Table 1 2019 World Health Organization classification of neuroendocrine neoplasms of the gastrointestinal tract and hepatopancreatobiliary organs

NENs	Differentiation	Grade	Mitotic rate	Ki-67 index %
NET, G1	Well differentiated	Low	< 2	< 3
NET, G2	Well differentiated	Intermediate	2-20	3-20
NET, G3	Well differentiated	High	> 20	> 20
NEC, small cell type	Poorly differentiated	High	> 20	> 20
NEC, large cell type	Poorly differentiated	High	> 20	> 20
MiNEN	Well or poorly differentiated	Variable	Variable	Variable

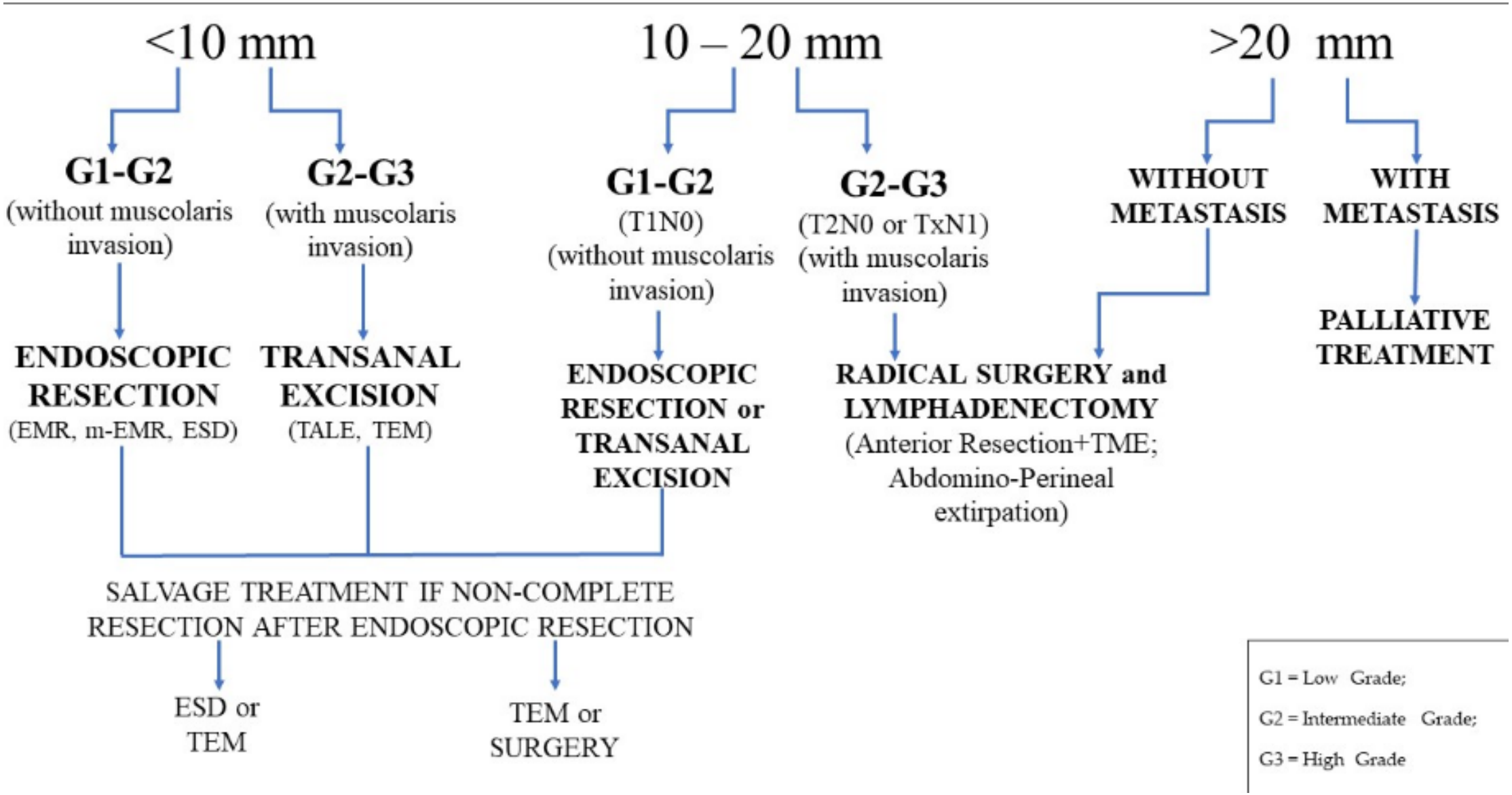
<10 mm
10 – 20 mm
>20 mm
G1-G2
(without muscolaris invasion)
G2-G3
(with muscolaris invasion)
G1-G2
(T1N0)
(without muscolaris invasion)
G2-G3
(T2N0 or TxN1)
(with muscolaris invasion)
WITHOUT METASTASIS
WITH METASTASIS
ENDOSCOPIC RESECTION
(EMR, m-EMR, ESD)
TRANSANAL EXCISION
(TALE, TEM)
ENDOSCOPIC RESECTION or TRANSANAL EXCISION
RADICAL SURGERY and LYMPHADENECTOMY
(Anterior Resection+TME; Abdomino-Perineal extirpation)
PALLIATIVE TREATMENT
SALVAGE TREATMENT IF NON-COMPLETE RESECTION AFTER ENDOSCOPIC RESECTION
ESD or TEM
TEM or SURGERY
G1 = Low Grade;
G2 = Intermediate Grade;
G3 = High Grade


The End